



PATIENT PRESENTING CLINICAL SIGNS

Beau Hubert Coughing with subsequent "hard swallow" 1-2 times a week for the last 8 months; no smokers or aerosols used in the home; CXR obtained to assess for intrathoracic pathology, in particular asthmatic or lower airway changes; upper resp PCR pending

SPECIES

Feline

RADIOGRAPHIC STUDY OF THE THORAX

Right/left lateral and ventrodorsal views of the thorax totaling 3 images are available for review.

BREED

RADIOGRAPHIC FINDINGS

DSH

Mild caudodorsal bronchial lung pattern is noted suggestive of early or mild chronic bronchial change. The interstitial and alveolar components of the lung present within normal limits. There is no evidence of interstitial pulmonary consolidation.

SEX

The cardiac silhouette presents normal in size and shape, the vertebral heart score is 7.5.

MN

The mediastinum is within normal limits.

AGE

Mild esophageal and gastric aerophagia likely secondary to intermittent swallowing episodes is seen.

5yr

Mild spondylosis deformans is present at T13-L1.

No evidence of pleural effusion or thoracic wall abnormality is noted.

INTERPRETED BY

Nele Eley (Ondreka),
DVM Dr. med. vet.,
DipECVDI

RADIOGRAPHIC DIAGNOSIS

- Mild caudodorsally accentuated bronchial lung pattern
- Mild esophageal and gastric aerophagia
- Normal radiographic presentation of the cardiovascular structures
- Mild thoracolumbar spondylosis T13L1, incidental

HOSPITAL NAME

DTLAVets

INTERPRETATION OF FINDINGS & FURTHER RECOMMENDATIONS

REFERRING VET

The radiographic study reveals a mild caudodorsally accentuated bronchial lung pattern, which may represent early or mild feline asthma/ allergic lower airway syndrome, or less likely chronic bronchitis, such as viral, bacterial, parasitic or protozoal.

Dr Castaneda

Correlation with the clinical signs and pending upper respiratory PCR results is recommended.

Thoracic CT or airway sampling such as BAL or TTW, could be considered for definitive assessment if coughing persists or worsens.

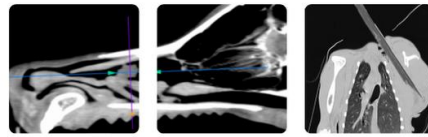
INVOICE

23428

Symptomatic management with environmental modification, such as reducing aerosol exposure and management for potential allergic lower airway syndrome can be considered as needed.

DATE

01/03/2026



PATIENT

Beau Hubert

SPECIES

Feline

BREED

DSH

SEX

MN

AGE

5yr

INTERPRETED BY

Nele Eley (Ondreka),
DVM Dr. med. vet.,
DipECVDI

HOSPITAL NAME

DTLAVets

REFERRING VET

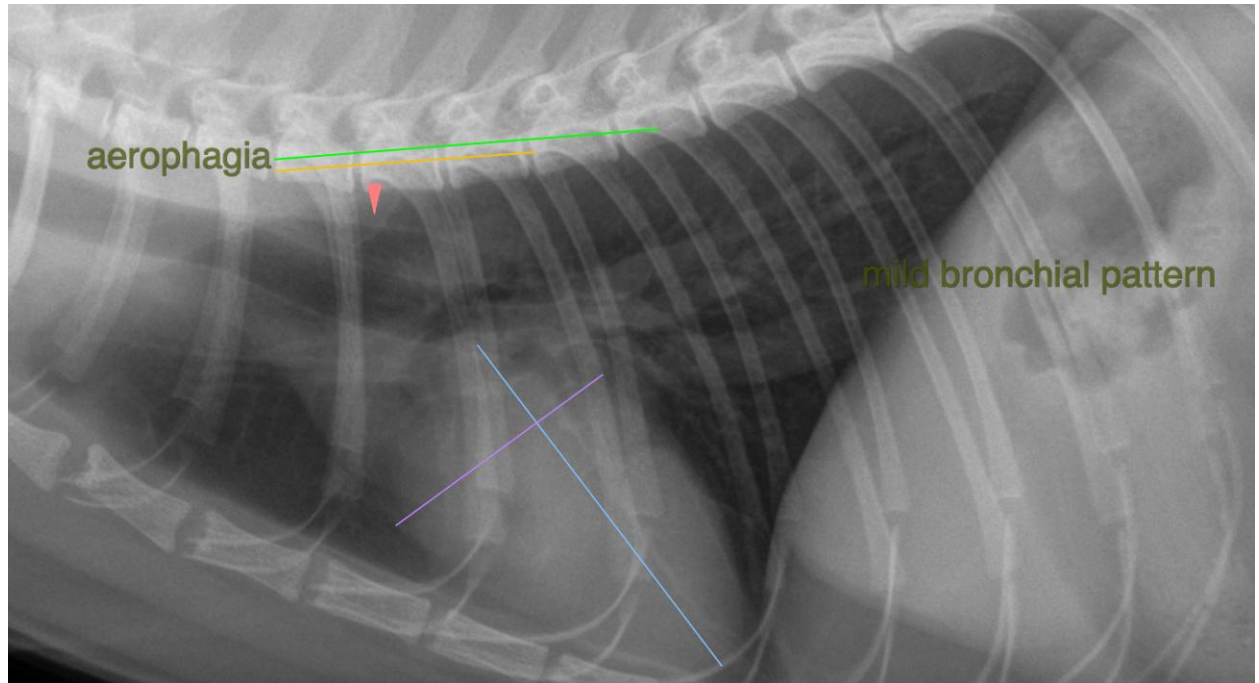
Dr Castaneda

INVOICE

23428

DATE

01/03/2026





PATIENT

Beau Hubert

The information and recommendations provided are based on the images presented by the referring veterinarian. No evaluation can be communicated regarding pathology that was not visible in the image/video clips provided.

SPECIES

Feline

Thank you for this referral. If the clinical or image interpretation does not parallel your findings or if I can be of any further assistance please contact me.

BREED

DSH

Nele Eley (Ondreka), DVM, Dr. med. vet., DipECVDI
European Specialist in Veterinary Diagnostic Imaging, Cert. Radiology,
Senior lecturer University of Giessen/Germany, Veterinary Faculty, Department of Radiology.
info@sonopath.com

SEX

MN

AGE

5yr

INTERPRETED BY

Nele Eley (Ondreka),
DVM Dr. med. vet.,
DipECVDI

HOSPITAL NAME

DTLAVets

REFERRING VET

Dr Castaneda

INVOICE

23428

DATE

01/03/2026